

Vertical Shortening Plication in Abdominoplasty, a New Technique. a Case-Series Study with Six Months Follow-Up

Mohamed F Abozeid^{1*}, Hossam Tahssen², and Omar M Nouh³

^{1,2}Lecturer of Plastic Surgery, Department of Plastic Surgery, Faculty of Medicine, Cairo University.

³Egypt. Department of Plastic Surgery, Faculty of Medicine, Cairo University, Egypt.

Abstract

Background: Residual abdominal wall bulge, owing to rectus abdominis muscle diastasis, has been hindering the aesthetic outcome in lipectomies over the past decades. The principal purpose of this case series was to explore the reliability of a new technique for midline vertical plication that strengthens the anterior rectus sheath both vertically and transversely for the improvement of the results regarding the aesthetic appearance and the long-term maintenance as well as long-term safety.

Methods: The study was conducted in Royal Hospital, Cairo, Egypt during the period from June 2014 to January 2017. The study included female patients undergoing abdominoplasty for a bulging abdominal wall. All patients were evaluated by detailed history, careful physical examination and photographed pre and postoperative.

Two separate prolene[®] 1 sutures were used in a zigzag fashion on either side of the midline to provide the desired effect, while hypnotic Vicryl[®] 0 figure of eight sutures were taken to reinforce the vertical plication. After surgery, all cases were followed up for six months to assess the outcomes of the procedure. The primary outcome measure was to assess the true and overt shortening as an objective assessment of the success rate of the technique.

Results: The 30 patients, in which this technique was adopted, were assessed concerning overt and true shortening of the abdominal wall. They had a mean age of 44.8±8.9 years and mean BMI of 33.7±2.6. The proposed technique warranted overt vertical shortening of the distance from the xiphisternum to the symphysis pubis ranging from 11 to 36% with a mean of 25%. The true shortening owing to rectus plication ranged from 19 to 33% with an average of 25%. Twenty-five patients (83%) were highly satisfied with the overall result. The most frequently encountered complication was superficial wound infection, while the most troublesome complication was midline wound dehiscence (n=2).

Conclusion: Finally, we can conclude that our new technique for midline vertical plication that strengthens the anterior rectus sheath both vertically and transversely has been demonstrated to be a reliable method to optimize the results of abdominoplasty. The technique proved to be successful with appealing results and also stood the test of time.

Keywords: Abdominoplasty; Lipectomy; Plication; Satisfaction, Complications.

Introduction

Early in the twentieth century, dermatolipectomies of hanging abdominal panniculi entailed removal of excess skin and underlying fat to rid the patient of hanging tissues, with minimal attention to aesthetic principles. In the latter half of the century, advances in abdominoplasty techniques led to improved scar placement, abdominal wall plication, and umbilical transposition [1, 2].

Significant technical refinements have been introduced in abdominolipectomy meet the growing perception of aesthetics among the general population and to handle the new challenges faced by surgeons such as weakness of the rectus abdominis muscles [3-6].

Restoring a normal waistline definition is the ultimate goal of many abdominoplasties [7]. The combined effects of pregnancy and aging on the abdominal wall include redundant skin, excess subcutaneous fat, and musculoaponeurotic flaccidity. Of course, these findings remain the most common clinical indications for abdominoplasty [4].

During abdominoplasty, rectus plication is commonly performed and aims to relocate the rectus muscles to the midline; thus, restores the abdominal contour. The classic Pitanguy technique [2], described in 1967, the fascia is plicated in the midline using a non-absorbable suture. Since then, different techniques and suture materials have been implicated for correction of rectus diastasis [7, 8].

The classic midline plication restores the anatomic integrity of the abdominal wall in the horizontal direction. However, the technique doesn't address the vertical laxity. Hence, attempts were made to incorporate a rather transversely oriented plication [8, 9]. The longevity of these techniques is debatable however compared to the durable of the midline plication [10]. In our current study, we will examine a new technique that combines both vertical shortening and plication of the linea alba that should, as we believe, provide the desired effect of

*Address for Correspondence: Dr. Mohamed Fathi Abozeid, 1190 Zahraa Nasr, Cairo, 11825, Egypt, Tel: +20-1066626060; E-mail: dr.mohamed.f.abuzeid@gmail.com; mabozeid75@gmail.com

Received: December 11, 2017; Date Accepted: December 30, 2017; Date published: January 02, 2018.

of waist definition and reduction of the bulge that often follows abdominoplasty utilizing only midline rectus plication..

Thus, the rationale intended for the current study was to explore the efficiency and safety of our new technique, the combination of vertical shortening and the plication of the linea alba as a reliable procedure for abdominoplasty.

We recruited 30 female patients, between 25 to 57 years, who were willing to undergo abdominoplasty for a bulging abdominal wall. Exclusion criteria included: American Society of Anesthesia score 3 or 4 (high risk for anesthesia), patients with organ failure, diabetes mellitus, and collagen vascular diseases, and patients with bleeding tendencies.

Patients and Methods

This case-series study was conducted during the period from June 2014 to July 2015 with six-month follow-up period in Royal Hospital, Cairo, Egypt. The goal of this study was clearly explained in the Arabic language to all subjects before their enrollment to the study, and an informed consent form was signed by and obtained from all of those enrolled.

Preoperative and Postoperative Patient Assessment

All patients were evaluated by detailed history, careful physical examination and photographed pre, intra and postoperative using Nikon d3200 DSLR Camera, 18-55 mm lens. Photography views were standard front and lateral views. Smoking was stopped at least three weeks before the procedure.

History included: age of the patient, history of cardiac problems, liver disease, renal disease or recent drug intake. Adequate physical examination with stress on the following points was done: the general examination includes signs of renal failure or liver disease. A detailed examination was done to assess for the degree of bulging in the abdominal wall.

We explained to the patient about the incision, the scars, the idea of the operation, discussion with her to know their expectations.

Patients were assessed preoperatively, immediately post-operation, and at one, three and six months post-operative follow-up. Photos were taken in each visit.

Laboratory Investigations

Blood samples were taken from patients as routine preoperative preparation for complete blood picture, coagulation profile and liver and kidney functions, random blood sugar.

Preoperative Markings

With the patient in the standing position, skin markings were made demarcating both the lower abdominal crease and the uppermost limit of the flap such that both were of equal lengths to eliminate dog ears. The midline and mid-clavicular lines were demarcated with stay sutures, and the distance from the xiphisternum to the symphysis pubis was measured [Figure 1].

Operative Technique

Operations in all cases were done under epidural anesthesia plus sedation.

First, the flap was excised as an initial step during the operation using a combination of sharp dissection near the midline and monopolar diathermy cautery for the more lateral areas. After that, the umbilicus was detached from the flap and preserved. Then, in the

supra-umbilical zone, flap elevation was continued limited laterally to the linea semilunaris as far as the xiphisternum cranially. Careful hemostasis was done. Next, an intraoperative measurement was taken from the xiphisternum to the symphysis pubis just before the midline plication [Figure 2]. After that, the line of the plication was marked using methylene blue dye extending along the muscle edges deviating laterally towards the umbilicus as shown in the photo [Figure 2].

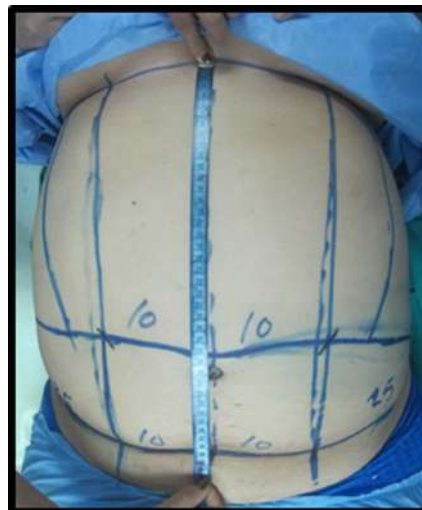


Figure 1: The preoperative markings and measurements.

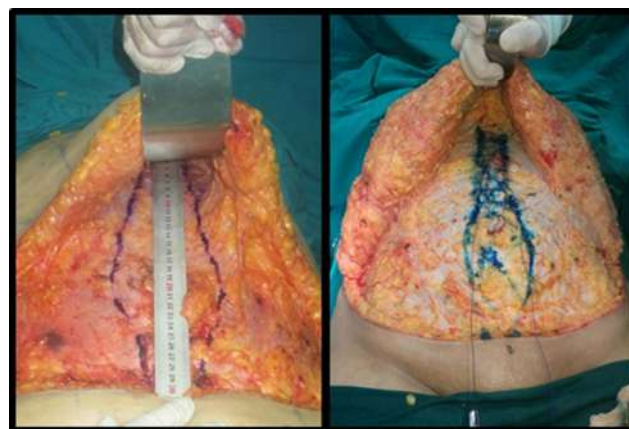


Figure 2: The intraoperative markings and measurements.

Then, two ampoules of non-absorbable monofilament (Prolene® 1) sutures were tied in the midline at the xiphisternum junction. Each was used to plicate the midline in a continuous seesaw fashion and was fanning as we proceeded towards the umbilicus, as shown in the illustration [Figure 3]. Multiple interrupted absorbable Vicryl® 2/0 hypnotic sutures were then used to reinforce the suture line.

After that, final measurements were obtained to assess the vertical shortening in the midline. Finally, the umbilicus was refashioned in its new position, the wound was closed eliminating the dog ears, and two suction drains were left.

Postoperative care

Antibiotics and anti-edematous oral medications were prescribed. Patients were instructed to wear pressure garment for a whole month. Sutures were removed on day 14 postoperatively. Serial photographs were taken during the follow-up visits over a six-months period.

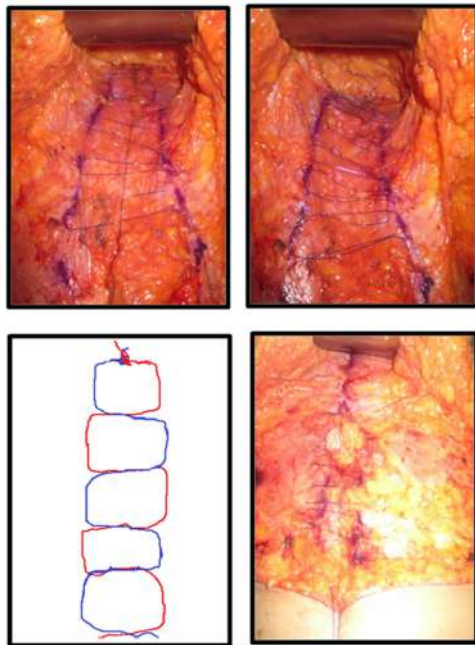


Figure 3: The technique for midline plication.

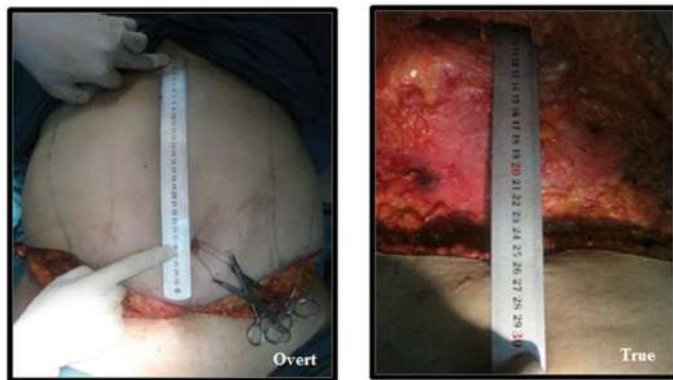

Figure 4: The final measurements.

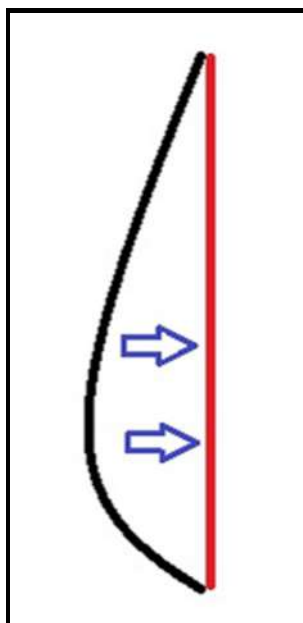


Figure 5: The desirable effect.

Outcome measures

The primary outcome measure was to assess the true and overt shortening as an objective assessment for the success of the technique.

We used the percent change in the true and overt length from pre-technique measurements and post- technique measurements by the aid of the following equation.

$$T = \frac{tP1 - tP2}{tP1} \times 100$$

$$O = \frac{oP1 - oP2}{oP1} \times 100$$

Where: T is the true shortening, O is the overt shortening, P1 is the preoperative measurements and P2 is the postoperative measurements (P2) in cm.

The secondary outcome measure was to quantify the short-term and long-term complications as well as to assess patients' satisfaction with results using a satisfaction scale where 3 is very satisfied (the results matched all the patient's desires), 2 is Satisfied (not all the expectations are met, but still satisfied and do not request re-operation or secondary procedure) and 1 unsatisfied (requiring re-operation or secondary procedure).

Statistical analysis

All statistical tests were done using a significance level of 95%. A value of $P < 0.05$ was considered statistically significant. SPSS software (Statistical Package for the Social Sciences, version 20.0, SSPS Inc, Chicago, IL, USA) was used for the statistical analyses. Data were presented as (mean \pm SD) or median (range) for continuous variables and as a frequency and percent for categorical variables. Comparisons were made using the paired t-test for continuous variables and Chi-square test for categorical variables.

Results

Baseline Characteristics

All thirty patients were female that have had bulging abdominal wall and eligible for abdominoplasty. The age of the patients ranged from 28 to 58 years (mean age: 44.8 ± 8.9). The mean Body Mass Index was 33.7 ± 2.6 with a minimum of 28.6 and a maximum of 38.3 Kg/cm^2 .

Smoking was the most predominant risk factor (23%, $n = 7$). Diabetes Mellitus was present in 17% of cases ($n=5$). Other risk factors included hypertension, bronchial asthma, HCV and ischemic heart ($n=4, 4, 2 \& 1$, respectively). Seventeen patients had previous abdominal operations; fourteen of them had Caesarian section. Twenty-four patients have had at least one pregnancy. None of the patients included in the study had abdominal wall hernias, as shown in Table 1.

Objective assessment of the technique: preoperative, intraoperative and postoperative measurements

The proposed technique warranted overt vertical shortening of the distance from the xiphisternum to the symphysis pubis ranging from 10 to 34% with a mean of 24.4%. The true shortening owing to rectus plication ranged from 18 to 32% with a mean of 25 %, as shown in Table 2.

Table 1: Baseline Characteristics.

	Mean ± SD (Min-Max)
Age in year	44.8±8.9 (28-58)
BMI Kg/cm ²	33.7 ±2.6 (28.6-38.3)
Number of patients (%)	
Smoking	7 (23%)
Hypertension	4 (13%)
DM	5 (17%)
Ischemic heart disease	1 (3%)
Bronchial asthma	4 (13%)
HCV	2 (7%)
Previous abdominal operations including CS	17 (57%)
Caesarian section	14 (47%)
Previous pregnancy	24 (80%)
Abdominal wall hernias	0 (0%)

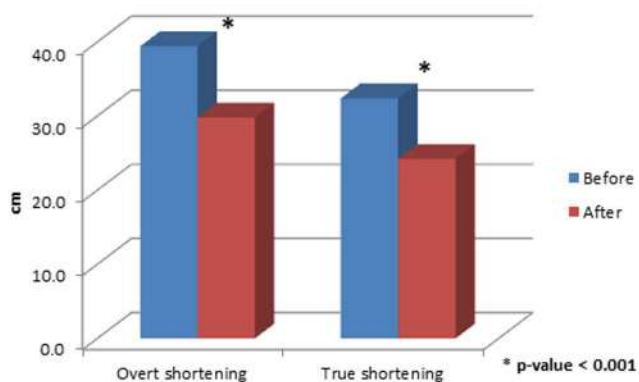


Figure 6: Preoperative and postoperative measurements.

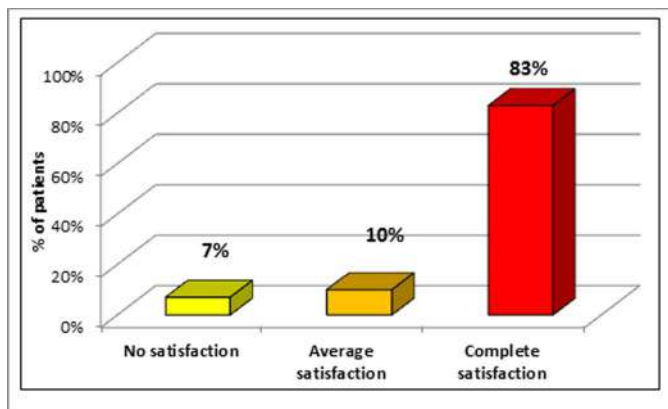
Table 2: Preoperative, intraoperative and postoperative measurements.

	Mean ± SD (Min-Max)	p-value
Overt length preoperative	39.4±3.4 (35.0-46.0)	< 0.001
Overt length postoperative	29.8 ±3.6 (24.0-38.0)	
Percent change	24.4%±6.2% (10%-34%)	
True length pre-technique	32.4±3.6 (27.0-41.0)	< 0.001
True length post-technique	24.2 ±2.4 (21.0-30.0)	
Percent change	25.0%±3.7% (18%-32%)	

Post -operative assessments: Patients' satisfaction

Twenty-five patients (83%) were highly satisfied with the overall result. While, three patients (10%) were satisfied but concerned about the abdominal tightness they feel. On the other hand, two patients (7%) found the outcome less than what they expected; mostly owing to misinterpretation of the preoperative counseling.

Figure 7: Patients' satisfaction.



Post -operative assessments: complications

None of the patients had a major life-threatening postoperative complication. Six patients (20%) had superficial wound infection. Four patients (13%) had residual dog ears that required further revision. Two patients (7%) had small midline wound dehiscence that warranted secondary sutures.

Table 3: Baseline Characteristics.

	Number of patients (%)
No complications	18 (60%)
Superficial wound infection	6 (20%)
Residual dog ears	4 (13%)
Wound dehiscence	2 (7%)

Figure 8: A 47 years old case: preoperative and 7-months postoperative.

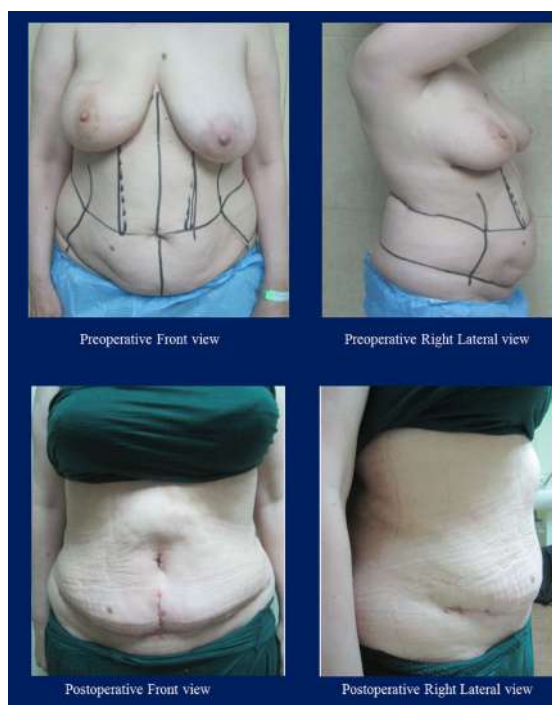

Figure 9: A 39 years old case: preoperative and 5-months postoperative.

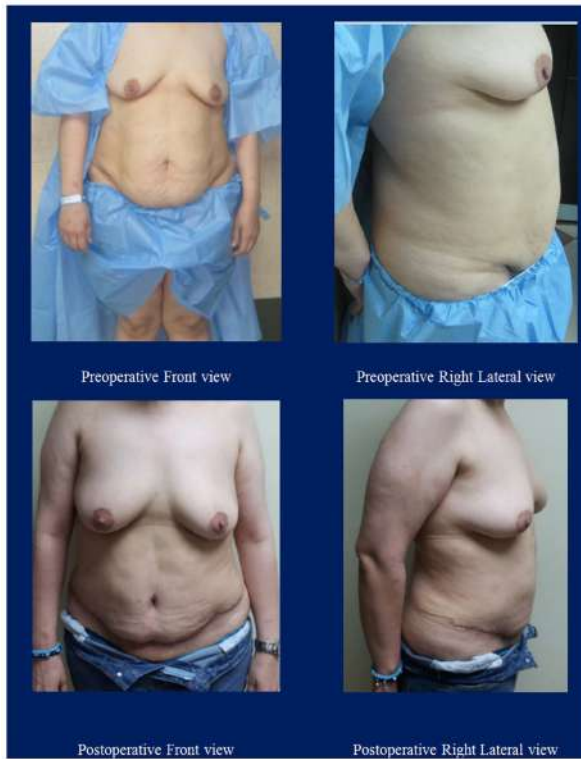

Figure 11: A 33 years old case: preoperative and 4-months postoperative.

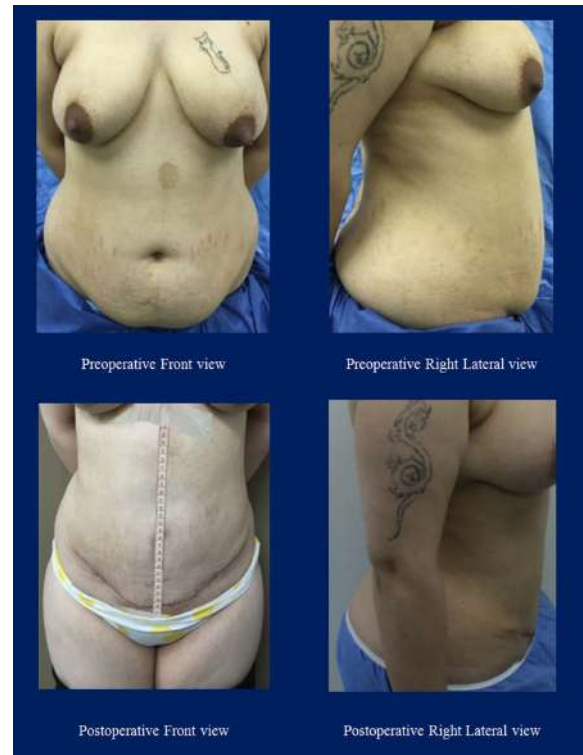
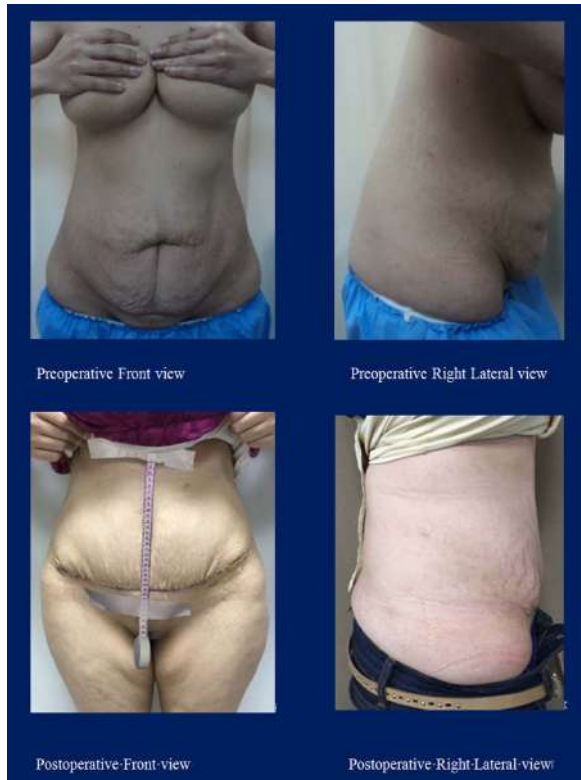
Figure 10: A 51 years old case: preoperative and 3-months postoperative.



Discussion

Our results demonstrated that our proposed abdominal wall plication technique was effective in controlling the anteroposterior bulge to achieve the aesthetically pleasing scaphoid abdomen. The procedure was successful in almost all cases with a high patients' satisfaction of the outcomes as a subjective measure of satisfaction added to the objective measurements preoperative, intraoperative and postoperative. All post-operative complications (wound problems or do ears) were resolved completely during the follow-up period after the appropriate actions.

In the latter half of the past century, vertical abdominal wall plication has been introduced to address the divarication of recti [2, 11]. This technique led to a dramatic improvement on the results of lipectomies through tightening of the abdominal wall width and hence was standardized in many centers all over the world [12].

The vertical plication of the abdominal wall technique is believed to have reached its popularity because it provided an anatomical correction of the problem already present in first place [13]. This, being achieved, led to long-lasting, durable results [10, 14, 15]. On the other hand, plastic surgeons attempted a variety of techniques to address the vertical laxity of the abdominal wall [8, 9, 16]. With limited evidence supporting the longevity of the plication.

Most commonly used, transversely oriented plication techniques were attempted in an extra-anatomical fashion, with the plication situated on the musculature of the abdominal wall [8, 9]. Hence, it was subjected to continuous shearing by the underlying muscles, and ultimately leading to lacking long-term evidence supporting their use.

Abramo and colleagues recommended the use of an H-shaped plication by the end of the twentieth century. They failed to provide any quantitative assessment for their patients and relied on subjective judgement [8]. In 2004, Yousif and coworkers recommended multiple additional transverse plication of the rectus abdominus muscle with promising results, but since then, data supporting their use have been deficient [9]. In 2010, Nahas and Ferreira recommended an L-shaped plication of the external abdominal oblique aponeurosis in addition to the midline plication to manage the bulging abdominal musculature. Their work, however, lacked supporting statistics [16].

What makes the proposed technique favorable is that it reduces both the vertical and transverse dimensions on a rather a fascial plane (the linea Alba). To do this, we used two non-absorbable continuous seesaw sutures instead of one to handle the two-dimensional reduction in a more stable fashion.

Although the plicated recti are best measured when the flap was elevated i.e. true shortening, the overt shortening is what matters to the subjects and is, therefore of equal importance when evaluating the results. The results of our study showed significant improvement in the diastasis both in the antero-posterior direction and transverse planes that did give not only appealing results but also stood the test of time.

Finally, we believe that this proposed novel technique with its maintained success in those types of patients is a reliable option than can be considered as it is a simple, rather effective and competent method to optimize the results of the abdominoplasty operations. Thus, further studies would be directed to evaluate to reproducibility of the technique on the long run.

Conclusion

In this case series, we can conclude that our new technique for midline vertical plication that strengthens the anterior rectus sheath both vertically and transversely has been demonstrated to be a reliable method to optimize the results of abdominoplasty. The technique

proved to be successful with appealing results that should stand the test of time.

References

1. Vernon S. Umbilical transplantation upward and abdominal contouring in lipectomy. *Am J Surg.* 1957; 94:490. [\[Crossref\]](#)
2. Pitanguy I. Abdominolipectomy. An approach to it through an analysis of 300 consecutive cases. *Plast Reconstr Surg.* 1967; 40:384. [\[Crossref\]](#)
3. Grazer FM. Abdominoplasty. *Plast Reconstr Surg.* 1973; 51:617-623. [\[Crossref\]](#)
4. Lockwood T. High lateral-tension abdominoplasty with superficial fascial system suspension. *Plast Reconstr Surg.* 1995; 96:603-608. [\[Crossref\]](#)
5. Planas J. The "vest over pants" Abdominoplasty. *Plast Reconstr Surg.* 1978; 61: 694-700. [\[Crossref\]](#)
6. Regnault P. Abdominal lipectomy, a low "W" incision New York: New York International Society of Aesthetic Plastic Surgery; 1972. [\[Crossref\]](#)
7. Mosaad BM and Frame JD. Medial Advancement of Infraumbilical Scarpa's Fascia Improves Waistline Definition in "Brazilian" Abdominoplasty. *Aesthet Plast Surg.* 2013; 37:3-10. [\[Crossref\]](#)
8. AbramoAC, CasasSG, Oliviera VR and Marques A. H-shaped, Double-Contour Plicatoin in Abdominoplasty. *Aesthet plast surg.* 1999; 23:260-266. [\[Crossref\]](#)
9. Yousif NJ, Lifchez SD and Nguyen HH. Transverse Rectus Sheath Plication in Abdominoplasty. *Plast Reconstr Surg.* 2004; 114: 778-784. [\[Crossref\]](#)
10. Tadiparthi S, Shokrollahi K, Doyle GS and Fahmy FS. Rectus Sheath Plication in Abdominoplasty: Assessment of its Longevity and a Review of the Literature. *J Plast Reconstr Aesthet Surg.* 2012; 65: 328-e332. [\[Crossref\]](#)
11. Pitanguy I. Body contour. *Am J Cosm Surg.* 1987; 4:283-298. [\[Crossref\]](#)
12. Richter DF, Stoff A. Abdominoplasty procedures. In Neligan PC, Warren R (ed.) *Plastic Surgery 3rd Edition, Aesthetic.* 2013. Saunders/Elsevier: 530-559. [\[Crossref\]](#)
13. Brauman D. Diastasis Recti: Clinical Anatomy. *Plast Reconstr Surg.* 2008. 122: 1564-1569. [\[Crossref\]](#)
14. Van Uchelen JH, Kon M and Werker PMN. The Long-Term Durability of Plication of the Anterior Rectus Sheath Assessed by Ultrasonography. *Plast Reconstr Surg.* 2001; 107: 1578-1584. [\[Crossref\]](#)
15. Passami EJ, Radwanski HN, Pitanguy I and Nahas F. Long-Term Ultrasonographic Evaluation of Midline Aponeurotic Plication during Abdominoplasty. *Plast Reconstr Surg.* 2013; 132: 333-338. [\[Crossref\]](#)
16. Nahas FX and Ferreira LM. Concepts on Correction of the Musculoaponeurotic Layer in Abdominoplasty. *Clin Plast Surg.* 2010; 37: 527-538. [\[Crossref\]](#)